

Ulnar Distraction Osteogenesis in the Treatment of Forearm Deformities in Children With Multiple Hereditary Exostoses

Stephen Refsland, MD,* Scott H. Kozin, MD,† Dan A. Zlotolow, MD†

Purpose To report on the outcomes of using ulnar lengthening combined with acute angular correction for the treatment of forearm deformities in patients affected by multiple hereditary exostoses (MHE). Our hypothesis was that this procedure would improve both radiographic measurements and clinical outcomes with minimal complications.

Methods A retrospective chart review was performed on patients who had a diagnosis of MHE and had undergone ulnar lengthening via a uniplanar external fixator over a 12-year period. Clinical outcomes such as range of motion, pain, and surgical complications were assessed. Radiographic changes were measured using interval radiographs.

Results The series included 17 patients. Median age at surgery was 7 years (range, 3–14 years). Median follow up was 55 months (range, 5–125 months). Improvements occurred in radial and ulnar radii of curvature, carpal slip, ulnar variance, and carrying angle at the elbow. There was 1 major pin track infection. There were 2 failures of the external fixator requiring exchange. Premature consolidation occurred in 1 case. Elbow, forearm, and wrist motion was not affected. Radiocapitellar joint congruency did not change. No patient reported pain at final follow-up.

Conclusions Our approach of using distraction osteogenesis of the ulna with angular correction in the radius and ulna as needed is able to correct carpal slip as well as to improve forearm bowing and elbow carrying angle. All of the patients maintained congruency of the radiocapitellar joint with no postoperative dislocations. Because of the low complication rate, the resolution of pain in patients who presented with pain, and the improvement of forearm bowing, this approach should be considered as a treatment option for children with MHE who are at risk for radiocapitellar dislocation. (*J Hand Surg Am.* 2016; ■(■): ■–■. Copyright © 2016 by the American Society for Surgery of the Hand. All rights reserved.)

Type of study/level of evidence Therapeutic IV.

Key words Multiple hereditary exostoses, forearm deformity, distraction osteogenesis, ulnar lengthening, multiple osteochondromas.

From the *Department of Orthopedics, Temple University Hospital; and the †Shriners Hospital for Children, Philadelphia, PA.

Received for publication November 18, 2015; accepted in revised form June 24, 2016.

No benefits in any form have been received or will be received related directly or indirectly to the subject of this article.

Corresponding author: Stephen Refsland, MD, St. Luke's/Roosevelt Hospital, CV Starr Hand Surgery Fellowship, 3rd Floor, Roosevelt Hospital, 1000 10th Ave., New York, NY 10019; e-mail: srefsland@gmail.com.

0363-5023/16/ ■ ■ -0001\$36.00/0
<http://dx.doi.org/10.1016/j.jhssa.2016.06.008>

MULTIPLE HEREDITARY EXOSTOSES (MHE) is an autosomal dominant genetic disorder of enchondral growth with a prevalence of 1 in 50,000.¹ The disease results from mutations in the tumor suppressor genes EXT1 and EXT2.^{2–5} Patients typically present in the first decade of life, with a median presenting age of 3 years.¹ Forearm deformities are found in 40% to 70% of patients with MHE.^{1,6} The typical forearm deformity is cubitus varus, often the result of shortening of the ulna with a

compensatory increased radial bow and dislocation of the radial head. A number of factors have been identified as being important contributors to the amount of ulnar shortening. These include the total load of osteochondromas, gender, and lesions of a sessile type.^{4,7-9} However, a study that compared loss of longitudinal growth with volume of tumor found no significant association, suggesting that osteochondromas are not “stealing” growth from the physis as previously postulated.¹⁰

Forearm dysfunction in MHE may be caused by shortening of the ulna, increased radial bowing, impingement of an osteochondroma on the interosseous membrane, radial head subluxation/dislocation, and abnormalities in the distal radioulnar joint (DRUJ).¹¹ Radial head dislocation has been associated with worse outcomes and higher pain scores.¹²⁻¹⁴ However, the natural history of a radial head dislocation is not known. There is evidence to suggest that adults with marked forearm deformity can function well^{11,15,16}; however, evidence also points to long-term disability in adults with forearm deformity.¹⁷ With such scant and contradictory evidence, the treatment of forearm deformity in MHE remains controversial.

Variable results have been reported with the use of ulnar lengthening to treat a radial head that is already dislocated.^{14,18} Prevention of radial head dislocation may be a better option than relocation, but the success of this strategy has not been established. Because tethering of the radius in a growing forearm can progress to a radiocapitellar dislocation, we consider any new onset of subluxation or any worsening of radiocapitellar subluxation grade in a growing forearm to be indicative of an impending dislocation. Our approach has been to treat forearm deformity in children with MHE when they have any of the following findings: painful range of motion of the forearm, a positive carpal slip (a measure of ulnar translation of the carpus), and/or an impending radiocapitellar dislocation. The purpose of this study was to assess the outcomes of our approach to correct forearm deformity in MHE, in which a gradual ulnar lengthening is combined with osteochondroma excision and corrective osteotomies as needed.

MATERIALS AND METHODS

After internal review board approval, a retrospective chart review was conducted to identify MHE patients treated with an ulnar osteotomy and external fixator placement. This was done by searching appropriate Current Procedural Terminology (CPT) and *International Classification of Diseases—Ninth Revision* (ICD-9) codes over the time period between 2002 and

2013. Nineteen patients were identified; only 17 patients were included owing to incomplete records. Basic demographic data and the details of surgery on all patients were collected.

Range of motion was obtained from the chart and was measured by the treating physicians (S.H.K. and D.A.Z.). Postoperative range of motion was the final value recorded in the chart. The type of range of motion recorded was forearm pronation and supination, elbow flexion and extension, and wrist flexion and extension.

Two fellowship-trained hand surgeons (S.H.K. and D.A.Z.) who specialize in pediatric cases treated all of the patients. All patients who had at least 1 of the indications previously stated were offered surgery. Surgery included excision of all or part of the ulnar osteochondroma, creation of an osteotomy in the middle one-third of the ulna, and application of a uniplanar external fixator (Minirail; Orthofix Ltd, Maidenhead, United Kingdom). Occasionally, a closing wedge osteotomy of the ulna and/or radius was used for acute correction of the cubitus varus. The surgeons made a subjective assessment of the amount of radial bowing to decide on the need for a corrective osteotomy. If they felt that the radial bow would not remodel and would limit motion, a radial closing wedge osteotomy was also performed. After surgery, lengthening was begun 7 to 10 days after application of the external fixator. It was continued until either premature consolidation or achievement of an ulnar-neutral to slightly ulnar-positive wrist. Lengthening was stopped short of neutral in cases in which distraction began to occur through the radiocarpal joint. Lengthening was performed at a prescribed rate of 1 mm/d, although the actual rate may have varied because it depended on patient compliance. The timing of removal of the external fixator depended on consolidation of the lengthened bone, as defined by the appearance of 3 cortices out of 4 on 2 orthogonal radiographic views, and took place in the operating room with the patient under general anesthesia.

The operative record was reviewed for details about the procedure. The postoperative records were reviewed for complications. We looked specifically for premature consolidation, nonunion, and pin-site complications, which were graded as minor or major based on whether or not they were managed as an outpatient or an inpatient.

The start and termination of lengthening were determined from the chart. Length of callotasis was measured on the last day of lengthening. The total length was recorded, as was the number of days of lengthening. The rate of lengthening was calculated from these 2 values. Whether or not the patient had pain

before surgery and then after the external fixator was removed was determined from the chart and recorded.

Radiographic measurements were made on the preoperative radiograph taken closest to the date of surgery. Radiographic measurements on the postoperative radiographs were made upon removal of the external fixator and reflected the best correction. The most recent follow-up films were used to assess final radial head coverage. Because the primary deformity in these patients is in the coronal plane, the majority of measurements were made on an anteroposterior (AP) study of the forearm with the forearm supinated. Some children had difficulty with full supination, and in these cases, the best AP study possible was performed. In this position, we could measure the type of deformity based on the Masada classification,¹⁹ distance of the tumor from the ulnar and radial physes, carrying angle of the elbow, radial articular angle, radius of curvature of the ulna and radius, carpal slip, ulnar variance, angle of ulnar and radial physes to their respective shafts, and radial inclination. If a dedicated elbow film was available, it was used to assess the amount of radiocapitellar congruity. If an elbow study was not available, measurements were made from the AP and lateral views of the forearm that included the elbow. This represented the best image available but may have led to inaccuracies.

Radiographic measurements

Masada classification: The Masada classification was used to describe the type of deformity before surgery as either I, IIa, IIb, or III.

Radius of curvature, ulnar variance, angle of the radial and ulnar physes, elbow carrying angle, radial articular angle: These measures were recorded both before and after surgery (Fig. 1).

Carpal slip: The amount of the lunate radial to a line drawn from the tip of the olecranon and the ulnar border of the radial epiphysis was measured. If greater than 50% of the lunate was radial to this line, it was defined as a negative carpal slip. Otherwise, less than 50% of the lunate radial to the reference line was defined as a positive carpal slip.^{19–22} Appropriate assessment of carpal slip required both an adequate AP of the carpal bones and an ossified lunate (Figs. 2, 3). If these were not present, carpal slip was not recorded.

Radial inclination: Radial inclination was measured in a similar way to adults and was represented by the angle subtended by lines made parallel to the radial articular surface and the longitudinal axis of the metaphyseal portion of the radius.

Amount of radial head coverage: Radial head coverage was broken into 5 groups, ranging from grade 1, completely concentric, to grade 5, dislocated. This measurement has not been used in previous studies and was developed by the authors. Our method was developed to measure whether an incongruous joint is improving over time. This measurement has not been validated (Table 1; Fig. 4).

One of the senior authors (D.A.Z.) graded each of the radiocapitellar joints blinded to the patient's identity. Results for both an AP and a lateral x-ray were recorded before surgery, after surgery, and for the last available examination. Averages of all preoperative and postoperative measures were calculated. The differences between these averages were compared using a paired *t* test. Statistical significance was set at a *P* value of .05.

Results

The records of 17 patients were reviewed. The demographic characteristics of the patients are listed in Table 2. All of the forearms were classified as Masada type I or IIb.

Details regarding the operative procedures are listed in Table 3. Four patients underwent 1 repeat osteotomy owing to recurrence of deformity. In all cases, no more than 1 reoperation was required.

There were 8 cases of minor pin-site infection, which resolved with oral antibiotics as an outpatient. There was 1 major pin-site infection that required admission to the hospital for intravenous antibiotics and removal of the external fixator. In 1 case, removal of the osteochondroma from the distal ulna destabilized the distal ulnar fragment. This distal ulnar fragment was treated with observation and went on to heal to the proximal stump. Mechanical failure of the external fixator's lengthening device occurred in 2 cases, requiring exchange of the device. After the device exchange, lengthening resumed without premature consolidation. There were no cases of nonunion or requirement for bone grafting. There was 1 case of premature consolidation.

The 5 patients who had pain before surgery had no pain after surgery. Table 4 shows the values for which the difference between the preoperative and the postoperative averages was statistically significant. Although our sample size was small, differences in the ulnar radius of curvature, radial radius of curvature, ulnar variance, and carrying angle were all statistically significant. When comparing radial articular angle, angles of the radial and ulnar physes, and radial inclination, there were no statistically significant differences but the sample was likely

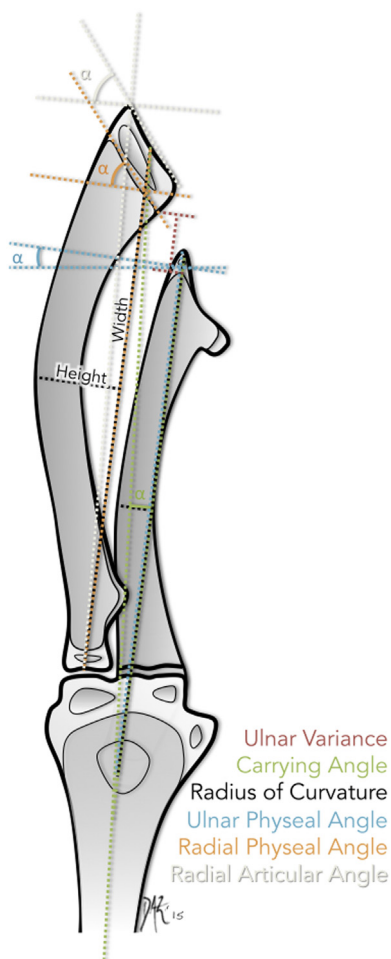


FIGURE 1: Radius of curvature. Measuring the ulnar and radial radii of curvature. The ulnar radius of curvature (black line) was determined by measuring the length of the ulna from the center of the proximal olecranon to the center of the distal epiphysis. The curvature was assumed to be a perfect sphere and the height of the arc was measured at the halfway point along the line. The radius of curvature was calculated using the height and width of the curve plugged into an online calculator found at the Web site <http://www.handymath.com/cgi-bin/rad2.cgi?submit=Entry>. The radial radius of curvature was determined in a similar manner. The ulnar variance (purple line) was measured as the distance from the lip of the ulnar metaphysis to the lip of the radial metaphysis. Negative numbers were representative of a shortened ulna. The ulnar physeal angle (blue line), α , is the angle between a line drawn parallel to the physis and a line depicting the axis of the ulna: from the tip of the olecranon to the tip of the ulnar epiphysis. An angle that was perpendicular was given a value of 0. Physes that angled toward the ulnar side were considered positive. Angles that tilted radially were considered negative. The radial physeal angle (yellow line), α , is the angle between a line drawn parallel to the physis and a line depicting the axis of the radius: from the middle of the radial head to the middle of the radial epiphysis. Angles that tilted in the typical ulnar direction were considered positive. Angles that tilted radially were considered negative. The elbow carrying angle (green line) was measured as α : the angle between a line from

underpowered to show a difference if one existed. Only 13 patients could be assessed for preoperative carpal slip. Of the 4 patients who had a negative carpal slip before surgery, all remained so. Nine surgeries were performed on patients with positive carpal slip before surgery. Seven of these procedures resulted in a negative carpal slip. Two patients remained positive after 1 ulnar lengthening. One of these cases became negative after repeat lengthening; the other did not.

Radiocapitellar joint grading improved after surgery in the 12 out of the 16 cases for which full measurements were available before surgery, after surgery, and at final follow-up. The 3 patients who were concentrically reduced and the 1 patient who was completely dislocated before treatment remained so after surgery. The rest of the patients who were intermediate grades all improved a grade. No patients became dislocated during the follow-up period of 5 to 125 months.

The range of motion results are shown in Table 5. Patients primarily had restriction in pronosupination. There were no clear improvements in the average range of motion after surgery. Total arc of motion changed from an average of 115° before surgery to an average of 127° after surgery. The patient who presented with a radiocarpal dislocation had full flexion and extension of his elbow and wrist. His limitation was only in pronation and supination.

DISCUSSION

Peterson²² reported that forearm deformity is the most common cause of dysfunction in patients with MHE. Forearm axis dysfunction may be influenced by ulnar length, gender, number of exostoses, and radial head dislocation.¹⁴ Stunted ulnar growth, itself, has been shown to be an independent risk factor for radial head dislocation.^{15,23} Radial head dislocation, in turn, has been associated with worse forearm rotation and overall worse function.^{12–14,18} Attempting to reduce an already dislocated radial head has been shown to be

the center of the tip of the olecranon to the center of the ulnar epiphysis and the anatomical axis of the humerus. An angle of 180° was considered as neutral. Numbers less than 180° were in varus. Numbers greater than 180° were elbows that were in valgus. The radial articular angle (gray line) is a measure of the deformity of the distal radius. It is measured by first drawing a straight line from the center of the radial head to the radialmost aspect of the radial epiphysis. A line perpendicular to this is then drawn. Another line is drawn parallel to the radial joint surface. The radial articular angle is defined as the angle α between the joint surface and the perpendicular line.

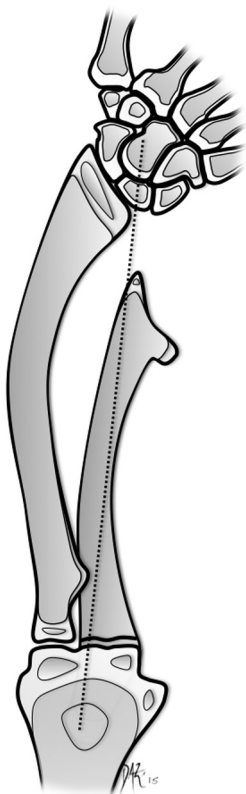


FIGURE 2: Negative carpal slip. A line is drawn from the tip of the olecranon to the ulnar border of the radial physis. When more than 50% of the lunate is radial to this line, carpal slip is negative. This represents greater than 50% of the lunate being covered by the radial articular surface.

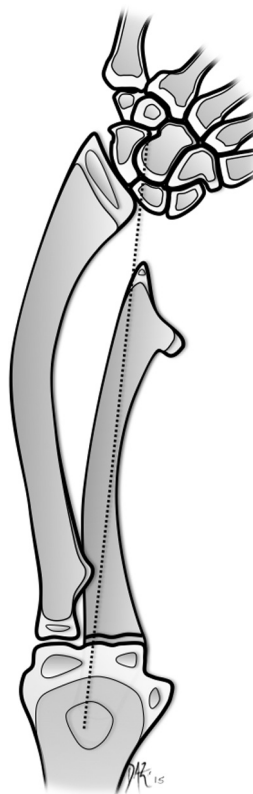


FIGURE 3: Positive carpal slip. When less than 50% of the lunate is radial to the previously defined line, carpal slip is positive.

difficult, suggesting that prevention is key.^{14,18,20} Because radial head relocation may lead to poor outcomes,^{12–14,18} our treatment algorithm has focused on attempting to prevent dislocation.

What type of surgery to perform and on which type of deformities remains controversial with a number of different treatments reported.^{6,12,15,18–22,24–31} Further controversy exists around surgical timing.^{11,15,16,19,21,22,24,28,30} Surgery in younger children takes advantage of greater remodeling potential and less severe deformity than in an older child. However, patients who undergo surgery at a younger age may have a higher risk of recurrence leading to a need for additional treatment. The connection between early presentation, worse deformity, and recurrence is probably related to the overall health and growth potential left in the disordered physis of the ulna.³² In this study, 4 children required repeat lengthening. They were ages 3, 5, 5, and 9 years at the first surgery. Three other children 5 years old or younger did not require repeat lengthening. This is consistent with the work done by Matsubara et al³² that suggested age was not a

TABLE 1. Radiocapitellar Subluxation Grading System

Grade	Value
1	Concentric
2	< 33% subluxated
3	33%–66%
4	< 100% subluxated
5	Dislocated

predictor of reoperation. Because there is no way of assessing the remaining growth potential of a radiographically open physis subjected to tethering, there is no way of predicting which deformity will recur.

We feel that any new onset of radiocapitellar subluxation or progression of existing subluxation warrants early surgery. Although the average subluxation grade showed an improvement in congruency with lengthening, the system of grading has not been validated and its reliability is unknown. Our patients did not show a loss of this reduction at final follow-up, which was between 5 and 125 months. This can be interpreted in 2 ways. Either our treatment stops further progression or these patients were never going to get

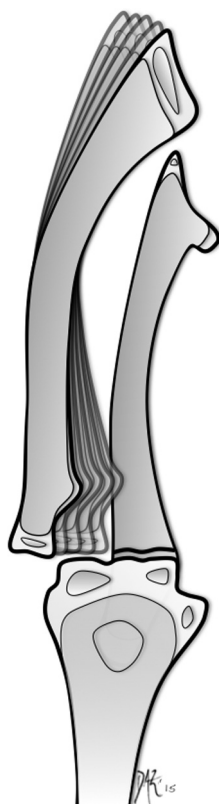


FIGURE 4: Radiocapitellar subluxation grade. The amount of radiocapitellar subluxation was graded based on splitting the radial head into thirds.

TABLE 2. Patient Demographics

Demographics	Values
Gender	Male—11 Female—6
Race	White—11 Hispanic—3 African American—3
Median age at surgery (y)	7 (range, 3–14)
Median follow-up (mo)	55 (range, 5–125)
Masada classification	Type I—10 patients Type IIb—7 patients

worse even without treatment. Unfortunately, our tools for assessment are not sufficiently refined for this purpose and further studies on radiocapitellar subluxation grading are needed to determine the effect of surgery.

At our institution, we use ulnar-based distraction osteogenesis for all Masada types I and IIb deformities. Our results suggest that ulnar lengthening in combination with closing wedge osteotomies, as needed, can significantly improve radiographic parameters such as radial and ulnar radii of curvature,

TABLE 3. Operative Details

Operative Details	Values
Average operative time (min)	97
Number of cases with other procedures	5
Concurrent osteochondroma excision	14
Acute angular correction anteroposterior plane	2 cases
Acute angular correction lateral plane	2 cases
Average velocity of lengthening (mm/d)	0.69
Average time to fixator removal (wk)	20 (range, 8–37)

ulnar variance, and carrying angle at the elbow. Pain was reliably relieved in all patients with preoperative pain. We had only 1 major complication, a deep pin-site infection. Radiocapitellar congruency seemed to be maintained and never worsened.

Results at the wrist were less satisfactory. Although carpal slip did improve in 7 of 8 patients with a positive carpal slip, other radiographic measures at the wrist did not improve. This may be due to the proximal location of our osteotomy. A middle third osteotomy treats the radius and the distal ulna as one unit owing to the robust association through the interosseous membrane. This could lead to proximal changes without affecting the distal forearm. Our assumption that untethering of the distal radial physis by lengthening the ulna would restore growth at the ulnar corner of the radius and, therefore, lead to remodeling of the distal radius was not correct. Although we were able to change carpal slip through changes in soft tissue tension, bony growth potential at the wrist did not respond to treatment. Ulnar lengthening may have been performed after irreversible physeal damage had occurred. Either an earlier intervention is needed to prevent physeal damage or this damage is a phenotypic variant that will be refractory to surgical treatment regardless of timing.

Range of motion of the forearm remained unchanged in our series. A total arc of 100° or greater is thought to be required for good forearm function.³³ In this study, preoperative average total arc of motion exceeded 100°, suggesting many of our children had good forearm rotation despite their preoperative deformity. Preservation of a functional arc in our cohort may be either because treatment was initiated prior to meaningful loss of motion occurred or because they would have had good motion regardless of treatment. Either way, our surgical approach did not negatively affect motion.

The limitations of this study include that it is retrospective and uncontrolled. Our patients come from far away and so follow-ups are not standardized

TABLE 4. Radiographic Measurements

Radiographic Parameter	Preoperative	Postoperative	P Value
Ulnar radius of curvature (mm)	226	341	< .05
Radial radius of curvature (mm)	226	273	< .05
Ulnar variance (mm)	−13	−2.9	< .05
Lateral radiocapitellar subluxation grade	1.9	1.3	< .05
Anteroposterior radiocapitellar subluxation grade	2.1	1.5	< .05
Carrying angle (°)	170	179	< .05

TABLE 5. Range of Motion

	Preoperative	Postoperative	P-value
Pronation (°)	52	62	.11
Supination (°)	63	65	.38
Total arc (°)	115	127	.20

and often performed elsewhere. Our records probably underestimate the true incidence of complications. For example, minor pin-site infections may have been triaged and treated at outside institutions without our knowledge or being recorded in our records. Pain assessment was not consistently addressed or recorded at every postoperative visit for all patients. We were only able to collect preoperative and postoperative pain assessment in 6 patients, which reflects upon the weakness of this parameter in our study.

We chose to measure postoperative radiographs immediately after external fixator removal to standardize our results. Only radiocapitellar subluxation grade was evaluated over time. We did not assess maintenance of deformity correction radiographically over time. We cannot say whether these corrections degrade with time.

Another limitation of our study was a lack of functional outcome measures. Some studies have suggested that those with MHE have limited functional impairment.^{11,15,34} In this study, functional impairment was not directly assessed. Our patients had a functional arc of forearm rotation at the start. We do not know what effect our treatment ultimately had on function.

Because our outcomes were primarily radiographic and relied on previously obtained, nonstandardized films, errors in measurement may have occurred. Some of our parameters can be difficult to accurately measure through radiographs, particularly because loss of forearm motion makes it difficult to obtain true orthogonal views. The radiographic parameters in this study have been previously used for evaluating surgical outcomes in patients with

MHE,^{11,19,20,21,23,25,26,28,32,34,35} yet have not been established to correlate with functional outcomes or patient satisfaction. Measurements like carpal slip have never had their reliability investigated. It is likely that lunate ossification and differences in forearm rotation would affect the reliability of carpal slip as a measurement of carpal translation and introduces error into our outcome assessment.

In this study, we found that distraction osteogenesis of the ulna can improve a number of radiographic parameters with a low complication rate. Radiocapitellar joint congruity is maintained and never worsens. For these reasons, ulnar lengthening should be considered as a treatment option for children with MHE who are at risk for radiocapitellar dislocation.

REFERENCES

- Schmale GA, Conrad EU III, Raskind WH. The natural history of hereditary multiple exostoses. *J Bone Joint Surg Am.* 1994;76(7):986–992.
- Ahn J, Ludecke HJ, Lindow S, et al. Cloning of the putative tumour suppressor gene for hereditary multiple exostoses (EXT1). *Nat Genet.* 1995;11(2):137–143.
- Legèai-Mallet L, Munnich A, Maroteaux P, Le Merrer M. Incomplete penetrance and expressivity skewing in hereditary multiple exostoses. *Clin Genet.* 1997;52(1):12–16.
- Taniguchi K. A practical classification system for multiple cartilaginous exostosis in children. *J Pediatr Orthop.* 1995;15(5):585–591.
- Sandell LJ. Multiple hereditary exostosis, EXT genes, and skeletal development. *J Bone Joint Surg Am.* 2009;91(Suppl 4):58–62.
- Shapiro F, Simon S, Glimcher MJ. Hereditary multiple exostoses. Anthropometric, roentgenographic, and clinical aspects. *J Bone Joint Surg Am.* 1979;61(6A):815–824.
- Porter DE, Lonie L, Fraser M, et al. Severity of disease and risk of malignant change in hereditary multiple exostoses. *J Bone Joint Surg Br.* 2004;86(7):1041–1046.
- Alvarez CM, De Vera MA, Heslip TR, Casey B. Evaluation of the anatomic burden of patients with hereditary multiple exostoses. *Clin Orthop Relat Res.* 2007;462:73–79.
- Carroll K, Yandow S, Ward W, Carey J. Clinical correlation to genetic variations of hereditary multiple exostosis. *J Pediatr Orthop.* 1999;19(6):785–791.
- Jones KB, Datar M, Ravichandran S, et al. Toward an understanding of the short bone phenotype associated with multiple osteochondromas. *J Orthop Res.* 2013;31(4):651–657.

11. Stanton RP, Hansen MO. Function of the upper extremities in hereditary multiple exostoses. *J Bone Joint Surg Am.* 1996;78(4):568–573.
12. Wood VE, Sauser D, Mudge D. The treatment of hereditary multiple exostosis of the upper extremity. *J Hand Surg Am.* 1985;10(4):505–513.
13. Gottschalk HP, Kanauchi Y, Bednar MS, Light TR. Effect of osteochondroma location on forearm deformity in patients with multiple hereditary osteochondromatosis. *J Hand Surg Am.* 2012;37(11):2286–2293.
14. Clement ND, Porter DE. Forearm deformity in patients with hereditary multiple exostoses: factors associated with range of motion and radial head dislocation. *J Bone Joint Surg Am.* 2013;95(17):1586–1592.
15. Arms DM, Strecker WB, Manske PR, Schoenecker PL. Management of forearm deformity in multiple hereditary osteochondromatosis. *J Pediatr Orthop.* 1997;17(4):450–454.
16. Noonan KJ, Levenda A, Snead J, Feinberg JR, Mih A. Evaluation of the forearm in untreated adult subjects with multiple hereditary osteochondromatosis. *J Bone Joint Surg Am.* 2002;84(3):397–403.
17. Goud AL, de Lange J, Scholtes VA, Bulstra SK, Ham SJ. Pain, physical and social functioning, and quality of life in individuals with multiple hereditary exostoses in the Netherlands. *J Bone Joint Surg Am.* 2012;94(11):1013–1020.
18. Hill RA, Ibrahim T, Mann HA, Siapkara A. Forearm lengthening by distraction osteogenesis in children: a report of 22 cases. *J Bone Joint Surg Br.* 2011;93(11):1550–1555.
19. Masada K, Tsuyuguchi Y, Kawai H, Kawabata H, Noguchi K, Ono K. Operations for forearm deformity caused by multiple osteochondromas. *J Bone Joint Surg Br.* 1989;71(1):24–29.
20. Akita S, Murase T, Yonenobu K, Shimada K, Masada K, Yoshikawa H. Long-term results of surgery for forearm deformities in patients with multiple cartilaginous exostoses. *J Bone Joint Surg Am.* 2007;89(9):1993–1999.
21. Pritchett JW. Lengthening the ulna in patients with hereditary multiple exostoses. *J Bone Joint Surg Br.* 1986;68(4):561–565.
22. Peterson HA. Deformities and problems of the forearm in children with multiple hereditary osteochondromata. *J Pediatr Orthop.* 1994;14(1):92–100.
23. Burgess RC, Cates H. Deformities of the forearm in patients who have multiple cartilaginous exostosis. *J Bone Joint Surg Am.* 1993;75(1):13–18.
24. Ip D, Li YH, Chow W, Leong JC. Reconstruction of forearm deformities in multiple cartilaginous exostoses. *J Pediatr Orthop B.* 2003;12(1):17–21.
25. Mader K, Gausepohl T, Pennig D. Shortening and deformity of radius and ulna in children: correction of axis and length by callus distraction. *J Pediatr Orthop B.* 2003;12(3):183–191.
26. Fogel GR, McElfresh EC, Peterson HA, Wicklund PT. Management of deformities of the forearm in multiple hereditary osteochondromas. *J Bone Joint Surg Am.* 1984;66(5):670–680.
27. Siffert RS, Levy RN. Correction of wrist deformity in diaphyseal aclasis by stapling. Report of a case. *J Bone Joint Surg Am.* 1965;47(7):1378–1380.
28. Vogt B, Tretow HL, Daniilidis K, et al. Reconstruction of forearm deformity by distraction osteogenesis in children with relative shortening of the ulna due to multiple cartilaginous exostosis. *J Pediatr Orthop.* 2011;31(4):393–401.
29. Waters PM, Van Heest AE, Emans J. Acute forearm lengthenings. *J Pediatr Orthop.* 1997;17(4):444–449.
30. Abe M, Shirai H, Okamoto M, Onomura T. Lengthening of the forearm by callus distraction. *J Hand Surg Br.* 1996;21(2):151–163.
31. Ishikawa J, Kato H, Fujioka F, Iwasaki N, Suenaga N, Minami A. Tumor location affects the results of simple excision for multiple osteochondromas in the forearm. *J Bone Joint Surg Am.* 2007;89(6):1238–1247.
32. Matsubara H, Tsuchiya H, Sakurakichi K, Yamashiro T, Watanabe K, Tomita K. Correction and lengthening for deformities of the forearm in multiple cartilaginous exostoses. *J Orthop Sci.* 2006;11(5):459–466.
33. Morrey BF, Askew LJ, Chao EY. A biomechanical study of normal functional elbow motion. *J Bone Joint Surg Am.* 1981;63(6):872–877.
34. Litzelmann E, Mazda K, Jehanno P, Brasher C, Penneçot GF, Ilharborde B. Forearm deformities in hereditary multiple exostosis: clinical and functional results at maturity. *J Pediatr Orthop.* 2012;32(8):835–841.
35. Shin EK, Jones NF, Lawrence JF. Treatment of multiple hereditary osteochondromas of the forearm in children. *J Bone Joint Surg Br.* 2006;88(2):255–260.